






Adenocarcinoma in Meckel's diverticulum: A rare case report

Alexander Mayer^{1,2} , Adam Kučera^{1,2} , Oleksandr Dobrovanov^{2,3} , Ivan Brychta^{1,2*} , Mária Vidiščák^{1,2} 

¹1st Surgical Clinic of the Slovak Medical University and University Hospital of Medicine, Academician Ladislav Derer Hospital, Bratislava, SLOVAKIA

²Slovak Medical University in Bratislava, Bratislava, SLOVAKIA

³A. Getlik Clinic for Children and Adolescents of Slovak Medical University and University Hospital of Medicine, Bratislava, SLOVAKIA

*Corresponding Author: ivan.brychta@dr.com

Citation: Mayer A, Kučera A, Dobrovanov O, Brychta I, Vidiščák M. Adenocarcinoma in Meckel's diverticulum: A rare case report. Electron J Gen Med. 2024;21(2):em572. <https://doi.org/10.29333/ejgm/14199>

ARTICLE INFO

Received: 25 Nov. 2023

Accepted: 03 Feb. 2024

ABSTRACT

Meckel's diverticulum (MD) is the most common congenital anomaly of the gastrointestinal tract. Its prevalence in the general population is 0.9-3.0%. Among the malignant neoplasms of MD, carcinoids and gastrointestinal stromal tumors are predominant. Adenocarcinomas account for less than 6.0% of all associated malignancies. We present a rare clinical case of a 67-year-old patient with gastric-type adenocarcinoma in MD, with metastatic foci in both lobes of the liver at diagnosis. This case demonstrates the diagnostic and therapeutic procedures that led to correct diagnosis and satisfactory treatment outcomes. This case emphasized the importance of using all the possibilities in the diagnosis and treatment and the necessity of cooperation with other experts in properly managing this disease. We also expressed an opinion about considering prophylactic resection of an intraoperatively discovered MD.

Keywords: Meckel's diverticulum, adenocarcinoma, metastases, liver, treatment

INTRODUCTION

Meckel's diverticulum (MD) is the most common congenital anomaly within the gastrointestinal tract, with a prevalence of 0.9-3.0% in the general population [1-3]. It is located 60-100 cm from the Bauhinia valve on the antimesenteric side of the ileum. It is a remnant of the embryonic tissue of the ductus omphaloentericus, part of which is preserved as an intestinal protrusion with a relatively wide mouth [1, 2]. In most of the population, it remains asymptomatic; however, it can lead to complications in 4.0-40.0% of cases. The most common complications include enterorrhagia, diverticulitis, mechanical ileus, and in rarer cases, a tumor or a combination of etiopathogenetic factors [4-7]. The epidemiology is briefly explained by the "rule of two" taken from American literature: length of the diverticulum (two inches [2x 2.54 cm]), location (two feet from the ileocecal valve [2x30.48 cm]), prevalence (2.0% of the population), commonly occurs at age two years, two times more common in men [1-3].

In the past, the gold standard for diagnosing complicated MD was enteroclysis, which was replaced by computed tomography (CT). In the case of a bleeding diverticulum, scintigraphy with the radioisotope, technetium (Tc-99m) or examination with radioisotope-labeled erythrocytes is suitable. Treatment consists of surgical resection of the affected section of the ileum and treatment of the complications mentioned above [4, 5].

The case reported herein involved one of the rare complications of MD, malignant neoplasia.

CASE PRESENTATION

A 67-year-old man was admitted to the 1st Surgical Clinic of the Faculty of Medicine of Slovak Medical University and University Hospital of Medicine in Bratislava for chronic abdominal pain with acute exacerbation over the last two days before admission. The patient had previously been treated conservatively with antibiotic therapy for suspected diverticulitis. The patient was examined on an outpatient basis before examination due to the presence of non-specific gastrointestinal symptoms. Given the age of the patient, examinations were carried out, including blood tests and tumor markers (CA19-9, CA72-4, and NSE). Tumor markers were borderline. Given that the patient had diverticulitis and suspected inflammation of MD, we thought that marginal moderate elevations in tumor markers might be due to diverticulitis or inflammatory bowel disease. The family history was unremarkable, and no oncological diseases were observed. Personal anamnesis included information about arterial hypertension, use of antihypertensive drugs, condition after appendectomy, and cholecystectomy. There was no history of allergies.

In the objective findings, the abdomen was slightly above the level of the chest, reflexes were normal, the flap was painful in both lower abdomens, palpation was more difficult with significant palpation sensitivity in the infraumbilical area and the right mesohypogastrium, with palpable resistance, the liver and spleen were not palpable, the inguinal floor was free, the scars after cholecystectomy and appendectomy were healed, firm, and without signs of herniation. Examination of

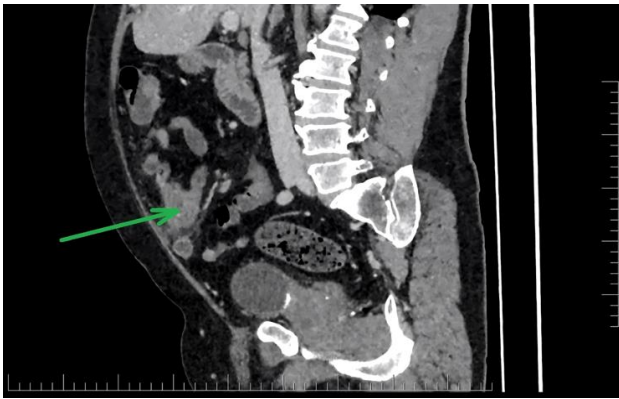

Figure 1. CT image in sagittal projection, MD infiltrate marked by an arrow (reprinted with permission of patient)

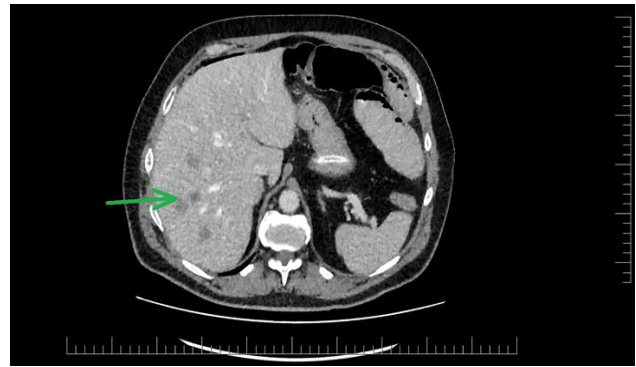


Figure 3. CT image from a whole-body staging examination in transverse plane showing multiple foci of liver metastases (reprinted with permission of patient)

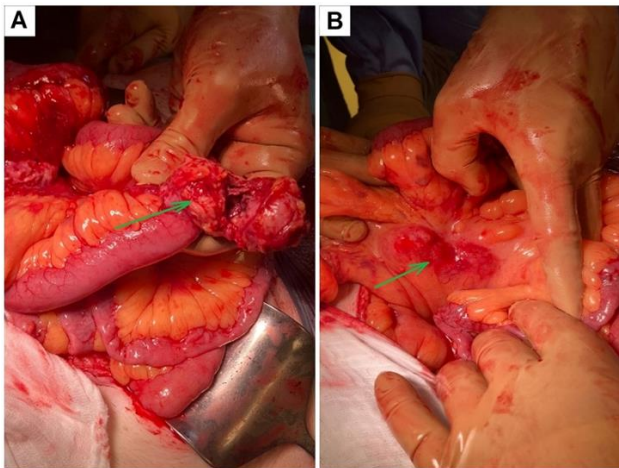


Figure 2. Intraoperative finding of tumor & mesenteric lymphadenopathy: Intraoperative finding of tumor infiltration of MD (A) & Intraoperative finding of mesenteric lymphadenopathy (B) (reprinted with permission of patient)

the rectum and other objective findings, except high blood pressure, revealed no pathological changes.

During hospitalization, the patient underwent a contrast-enhanced CT scan of the abdomen and pelvis, which revealed an inflammatory MD and multiple nonspecific cystoid deposits in the liver (**Figure 1**).

If there are signs of recurrence of inflammation, the presence of signs of an acute abdomen, possible peritonitis, an operation under anesthesia is indicated. A laparoscopic exploration of the abdominal cavity was performed with an intraoperative finding of an inflamed convoluted intestinal loop of the ileum and an inflamed MD, with significant mesenteric lymphadenopathy and multiple focal changes in the liver, suggesting metastasis.

Due to the unclear structure and difficult-to-mobilize convolution of the small intestinal loops, laparoscopy was performed, and access to the abdominal cavity was achieved through a median laparotomy (**Figure 2**). Segmental resection of the convolution of the intestinal loops of the ileum with side-to-side isoperistaltic enteroanastomosis was performed.

There was a deserted section on the serosa of the ileum, and the lumen of MD was filled with tumor masses. The resection was sent for histological examination, and an omentectomy was performed because of suspected tumor infiltration of the greater omentum.

The postoperative adaptation was satisfactory, with clinical signs of passage restoration indicating the sufficiency of the constructed enteroanastomosis. The development of clostridial enterocolitis complicated further hospitalization (samples were positive for *clostridium difficile* antigen and toxin), which was successfully treated with macrolides (vancomycin per os).

Because of suspected liver deposits detected intraoperatively and during the initial CT examination, we extended the diagnosis with a follow-up diagnostic protocol. Magnetic resonance imaging of the liver was performed natively and subsequently with a contrast agent (intravenous Gadovist), with the conclusion of multiple foci of involvement of the liver versus a metastatic nature with a fibrous component (in differential diagnosis -atypical hemangiomas or atypical secondary-infected focal processes) (**Figure 3**). As part of the differential diagnosis, a full-body staging CT was performed without verification of pulmonary metastasis, and autoimmune thyroiditis was diagnosed in the presence of nodular goiter without signs of primary thyroid cancer.

Further hospitalization was again complicated by the development of symptoms of intestinal obstruction, with a CT finding of mechanical ileus, and surgical revision was indicated. Perioperative findings of incipient plastic peritonitis and an adhesively altered anastomosis firmly fixed to the mesentery in the operative wound subdermally revealed a purulent collection of abscesses. Adhesiolysis and milking of the intestinal contents with verification of the mechanical patency of the entero-enteroanastomosis were performed using a vacuum wound healing system, "VAC seal Renasys" on the surgical wound.

After adequate refeeding, verification of the mechanical patency of the anastomosis, and diagnostic follow-up, the patient was discharged home for outpatient care.

Due to the ambiguous characteristics of focal changes in the liver, the Nuclear Medicine Clinic of the Oncology Institute of St. Elizabeth in Bratislava was consulted to perform a whole-body examination with positron emission tomography and computed tomography (PET/CT). The results of the whole-body PET/CT using 18-fluorodeoxyglucose revealed multiple hypermetabolic foci and the nature of metastases in both lobes of the liver and, according to CT, the size progression since the previous examination described hypermetabolic lymphadenopathy in the mesentery and ambiguous hypermetabolic focal findings in the colon ascendens and the

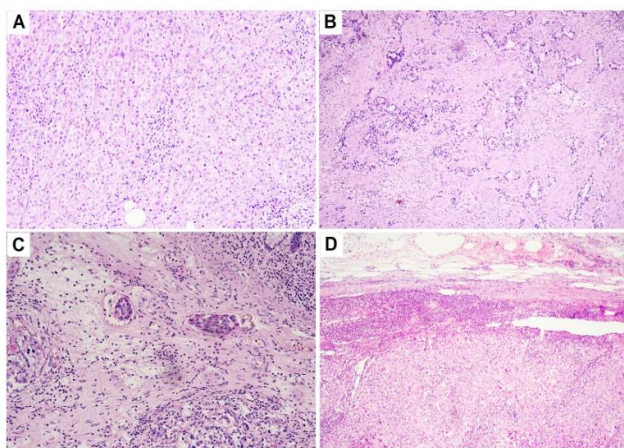


Figure 4. Histology of adenocarcinoma, NOS, gastric type low-grade G2 in MD (Source: Authors' and laboratory "Cytopathos" archive, Bratislava, Slovakia)

surgical wound (vs healing per second intention; however, implantation metastatic involvement could not be ruled out).

Finally, the histological findings confirmed the presence of gastric-type adenocarcinoma in MD (**Figure 4**). Captured omentum was without tumor changes.

After examination, the patient was discharged to the oncology clinic for management and further therapy.

DISCUSSION

Benign neoplasm is the most common among MD tumors, and malignant transformation is reported in 0.5-3.2% of all reported cases [8]. Among the malignant neoplasms, carcinoids (84.6%), gastrointestinal stromal tumors (8.0%), and MD adenocarcinomas account for less than 6.0% of all associated malignancies. Their prognosis is generally unfavorable because of late detection and advanced stages at the time of detection.

According to [9] and the data from the Mayo Clinic electronic records study, up to 89.5% of the cases in the observed sample were coincidental findings [9]. In the sample of 402 observed patients, men predominated, with a preponderance of 261 to 118 and a median age of 58. Of these samples, only 24 were adenocarcinomas without further specification of the tumor's histological nature, that is, without differentiation of gastric/intestinal type. Up to 104 patients were in the stage of metastatic involvement at diagnosis.

Considering the above data and the incidence of MD complications, such as malignant neoplasia, we conclude that the probability of developing adenocarcinoma in MD is negligible but possible [10-12]. Therefore, this is a rare case. In addition, we want to point out that MD may not manifest itself in any way. However, in the case of its inflammation, it can simulate the clinical picture of acute appendicitis. Therefore, during appendectomy, surgeons must revise the small intestine to a distance of approximately 100 cm.

Opinions on the prophylactic resection of MD differ, given its relatively high prevalence in the general population and relatively low incidence of associated complications [13]. According to findings of the latest analytical data, some believe that resection of incidental MD should be reserved for at-risk

population (men under 40 years, diverticulum longer than two cm, and presence of macroscopic mucosal changes) [13].

However, owing to the high risk of late detection of the tumor and its associated metastases, resection should be considered for every intraoperatively detected MD [13, 14].

In the differential diagnosis between MD and malignant tumors, additional research methods (CT, magnetic resonance, in some cases biopsy) and tumor markers play an important role. That is why, in our clinical case, we wanted to emphasize that in case of inflammation of MD, one should think about malignant neoplasms, although this is rare. In our case report we had information about a possible oncological disease (boundary tumor markers), the result of CT, but we did not have time to conduct additional examinations - they were planned. The fact is that the patient's condition worsened, an acute abdomen developed with signs of possible peritonitis or perforation (which, as found out during the operation, was covered). Therefore, the priority, in the first place, was to save the patient's life, and then additional examinations.

CONCLUSIONS

The rare complications of MD are either benign or malignant. Among malignant neoplasms, carcinoids predominate, and the prevalence of MD adenocarcinomas is less than 6.0% of all associated malignancies. The prognosis depends on the stage of the disease at the time of diagnosis but is generally unfavorable due to late detection and advanced stage at the time of detection.

With this case report, we want to point out that in cases of inflammation or symptomatic MD, one must also think about possible associated complications, which, in the event of their detection, must be dealt with in a multidisciplinary manner.

Author contributions: All authors have sufficiently contributed to the study and agreed with the results and conclusions.

Funding: No funding source is reported for this study.

Ethical statement: The authors stated that the study was reviewed and approved by the Ethics Committee of Academician Ladislav Derer Hospital on 3 May 2023 with approval number 795/05. The patient provided written informed consent to participate in this study. Written informed consent was obtained from the patient to publish potentially identifiable images or data in this article.

Declaration of interest: No conflict of interest is declared by authors.

Data sharing statement: Data supporting the findings and conclusions are available upon request from the corresponding author.

REFERENCES

1. Hansen C-C, Søreide K. Systematic review of epidemiology, presentation, and management of Meckel's diverticulum in the 21st century. *Medicine (Baltimore)*. 2018;97(35):e12154. <https://doi.org/10.1097/MD.00000000000012154> PMID: 30170459 PMCID:PMC6392637
2. Vidišćák M. *Novorodenecká chirurgia I [Neonatal surgery I]*. Krivá: M-Servis; 2008.
3. Fusco JC, Achey MA, Upperman JS. Meckel's diverticulum: Evaluation and management. *Semin Pediatr Surg*. 2022;31(1):151142. <https://doi.org/10.1016/j.sempedsurg.2022.151142> PMID:35305798

4. Keese D, Rolle U, Gfroerer S, Fiegel H. Symptomatic Meckel's diverticulum in pediatric patients-case reports and systematic review of the literature. *Front Pediatr*. 2019;7:267. <https://doi.org/10.3389/fped.2019.00267> PMID: 31294008 PMCID:PMC6606722
5. Tiu A, Lee D. An unusual manifestation of Meckel's diverticulum: Strangulated paraumbilical hernia. *N Z Med J*. 2006;119(1236):U2034.
6. Shaprynsky V, Nazarchuk O, Faustova M, et al. Some aspects of infectious complications in patients with surgical diseases. *Lekársky Obzor*. 2020;69(7-8):257-60.
7. Suhardja TS, Kua H, Hrabovszky Z. *Helicobacter pylori* colonisation in heterotopic gastric mucosa in Meckel diverticulum: Case report and review of the literature. *Clin Med Insights Case Rep*. 2019;12:1179547619846088. <https://doi.org/10.1177/1179547619846088> PMID: 31105433 PMCID:PMC6501473
8. Kabir SA, Raza SA, Kabir SI. Malignant neoplasms of Meckel's diverticulum; an evidence based review. *Ann Med Surg (Lond)*. 2019;43:75-81. <https://doi.org/10.1016/j.amsu.2019.05.017> PMID:31245001 PMCID:PMC6582065
9. van Malderen K, Vijayvargiya P, Camilleri M, Larson DW, Cima R. Malignancy and Meckel's diverticulum: A systematic literature review and 14-year experience at a tertiary referral center. *United European Gastroenterol J*. 2018;6(5):739-47. <https://doi.org/10.1177/2050640617752771> PMID:30083336 PMCID:PMC6068795
10. Principe DR, Nesper P, Metropulos AE, Rubin J, Marinov MN. Intestinal adenocarcinoma originating from an undiagnosed Meckel's diverticulum. *J Surg Case Rep*. 2022;2022(5):rjac128. <https://doi.org/10.1093/jscr/rjac128> PMID:35611002 PMCID:PMC9124546
11. Zhao Y, Yang X, Ye Y. Adenocarcinoma located at a Meckel's diverticulum: A case report and literature review. *J Cancer Res Ther*. 2017;13(5):878-81. https://doi.org/10.4103/jcrt.JCRT_124_17 PMID:29237920
12. Kusumoto H, Yoshitake H, Mochida K, Kumashiro R, Sano C, Inutsuka S. Adenocarcinoma in Meckel's diverticulum: Report of a case and review of 30 cases in the English and Japanese literature. *Am J Gastroenterol*. 1992;87(7):910-3.
13. Robijn J, Sebrechts E, Miserez M. Management of incidentally found Meckel's diverticulum a new approach: Resection based on a risk score. *Acta Chir Belg*. 2006;106(4):467-70. <https://doi.org/10.1080/00015458.2006.11679933> PMID:17017710
14. Caraccappa D, Gullà N, Lombardo F, et al. Incidental finding of carcinoid tumor on Meckel's diverticulum: Case report and literature review, should prophylactic resection be recommended? *World J Surg Oncol*. 2014;12:144. <https://doi.org/10.1186/1477-7819-12-144> PMID:24884768 PMCID:PMC4031372