







Parathyroid apoplexy from giant adenoma with mediastinal extension: A case report

José Paz-Ibarra^{1,2} , Marcio José Concepción-Zavaleta^{3*} , Fernando Quinto-Reyes^{1,2} ,
Julio César Alvarez-Gamero^{2,4} , José Somocurcio-Peralta^{1,5} , Juan Eduardo Quiroz-Aldave⁶ 

¹ Department of Medicine, School of Medicine, Universidad Nacional Mayor de San Marcos, Lima, PERU

² Division of Endocrinology, Hospital Nacional Edgardo Rebagliati Martins, Lima, PERU

³ Universidad Científica del Sur, Lima, PERU

⁴ Universidad Peruana Cayetano Heredia, Lima, PERU

⁵ Department of Anatomic Pathology, Hospital Nacional Edgardo Rebagliati Martins, Lima, PERU

⁶ Division of Non-Communicable Diseases, Endocrinology Research Line, Hospital de Apoyo Chepén, Chepén, PERU

*Corresponding Author: marcio_conc_zav@outlook.es

Citation: Paz-Ibarra J, Concepción-Zavaleta MJ, Quinto-Reyes F, Alvarez-Gamero JC, Somocurcio-Peralta J, Quiroz-Aldave JE. Parathyroid apoplexy from giant adenoma with mediastinal extension: A case report. *Electron J Gen Med.* 2024;21(6):em611. <https://doi.org/10.29333/ejgm/15582>

ARTICLE INFO

Received: 25 May 2024

Accepted: 14 Aug. 2024

ABSTRACT

Introduction: Primary hyperparathyroidism (PHPT) results from an excess secretion of parathyroid hormone (PTH), primarily due to parathyroid adenomas. These adenomas are more prevalent in women and, although rare, can develop into giant adenomas. One infrequent but notable complication of giant adenomas is parathyroid apoplexy. The aim of this manuscript is to describe the case of a Peruvian female patient diagnosed with PHPT secondary to a giant parathyroid adenoma, whose surgical treatment confirmed its apoplexy.

Case report: A 42-year-old Peruvian woman with hypertension and stage IV chronic kidney disease presented with a non-productive cough, dysphonia, and acute chest pain, revealing a mediastinal tumor on imaging. Physical examination showed no cervical tumors, and biochemical tests revealed elevated levels of total calcium and intact PTH, while serum phosphorus and calcitonin levels were normal. Imaging elucidated a parathyroid adenoma with mediastinal extension. Surgical intervention involved right parathyroidectomy, unveiling a 6 × 6 cm tumor with cystic and hemorrhagic degeneration, confirming the diagnosis of parathyroid apoplexy from a giant adenoma.

Conclusions: Giant parathyroid adenoma should be considered in patients presenting with a mediastinal mass and hypercalcemia. This condition can be complicated by parathyroid apoplexy in the context of PHPT. Timely imaging and surgical intervention are crucial for achieving optimal outcomes, with diagnosis confirmed through histopathology.

Keywords: parathyroid glands, primary hyperparathyroidism, parathyroid neoplasms, apoplexy, infarction, case report

INTRODUCTION

Primary hyperparathyroidism (PHPT) is characterized by excessive secretion of parathyroid hormone (PTH), leading to hypercalcemia, hypercalciuria, and hypophosphatemia. The most common cause of PHPT is a parathyroid adenoma, a benign entity that typically occurs sporadically in the majority of cases, although it can also be associated with genetic syndromes such as multiple endocrine neoplasia [1]. It is more frequently reported in women [2]. Parathyroid adenomas are usually small, with an average weight of 0.61 grams; however, giant parathyroid adenomas, which weigh more than 3.5 grams, occur much less frequently [3]. Pathological studies less frequently describe areas of infarction or hemorrhage in the parathyroid adenoma, referred to as parathyroid apoplexy [4].

The aim of this manuscript is to describe the case of a Peruvian female patient diagnosed with PHPT secondary to a giant parathyroid adenoma associated with its apoplexy. The

patient was treated surgically and subsequently showed favorable evolution.

CASE REPORT

A 42-year-old woman with a history of hypertension and stage IV chronic kidney disease, no significant family or surgical history, presented with symptoms including a non-productive cough, dysphonia, and acute chest pain associated with a mediastinal tumor. The tumor was detected on imaging studies two months prior to hospital admission, delayed due to the circumstances of the COVID-19 pandemic.

Physical examination revealed a patient in fair general condition, well-nourished, and hydrated, with a weight of 62 kg, height of 1.55 m, and a body mass index of 25.8 kg/m². Vital signs were within normal limits. No cervical tumors were palpable, and no significant abnormalities were noted in other organ systems.

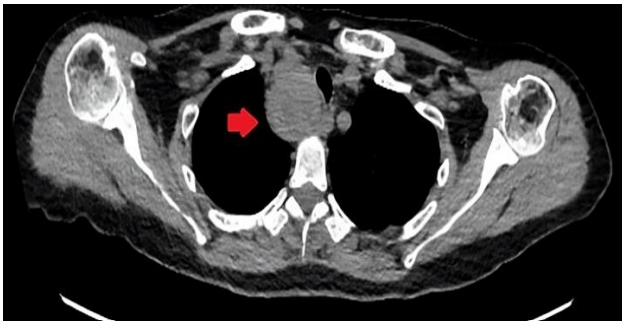

Figure 1. Cervical CT without contrast–Axial view (the red arrow indicates the mediastinal mass) (reprinted with permission of patient)

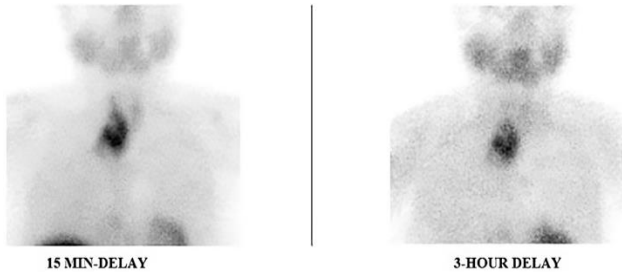


Figure 2. Parathyroid sestamibi scintigraphy (a hypercaptant giant parathyroid tumor is evident in the late phases at 15 minutes and 3 hours post administration of the radiopharmaceutical) (reprinted with permission of patient)

Biochemical tests revealed the following: total calcium: 12.8 mg/dL (reference value [RV]: 8.70-10.40 mg/dL), serum phosphorus: 3.75 mg/dL (RV: 2.4-5.1 mg/dL), serum creatinine: 2.2 mg/dL, cGFR (CKD-EPI): 26,8mL/min/1.73 m², alkaline phosphatase: 134 U/L (RV: 46-116 U/L), intact PTH: 269 pg/mL (RV: 11-67 pg/mL), and calcitonin < 2 pg/mL (RV: ≤19 pg/mL). Thyroid ultrasound revealed the presence of a predominantly cystic mixed lesion, located in the lower posterior region of the right thyroid lobe, with consideration of dependence on the parathyroid gland. It exhibited peripheral vascularity with extension into the mediastinum and measured approximately 21 × 17 × 17 mm. Ultrasound-guided fine-needle aspiration biopsy showed scant cohesive groups of cells, in addition to macrophages with hemosiderin pigment. Immunocytochemistry on the cell block was negative for thyroid transcription factor-1. PTH determination was not achieved with needle washing. Computed tomography (CT) showed a mediastinal tumor measuring 5 cm in diameter with tracheal compression, as well as bilateral nephrocalcinosis (**Figure 1**). 99mTc-sestaMIBI scintigraphy demonstrated a hypercaptant lesion compatible with right parathyroid adenoma with heterogeneous radiotracer uptake (**Figure 2**). With all these auxiliary examination results, we were confronted with a patient diagnosed with PHPT due to a right parathyroid adenoma with mediastinal extension.

As part of the preoperative medication administered the day prior to surgery, the patient received hydration, pamidronate 60 mg via infusion, cholecalciferol 100,000 units, and furosemide 40 mg at 8 am and 4 pm. The patient underwent right parathyroidectomy, revealing a 6 × 6 cm tumor, consistent with an encapsulated parathyroid gland tumor weighing 20 grams, indicative of a giant adenoma with cystic degeneration and hemorrhagic focus; the reagent for parafibrin was not available in our hospital (**Figure 3**).

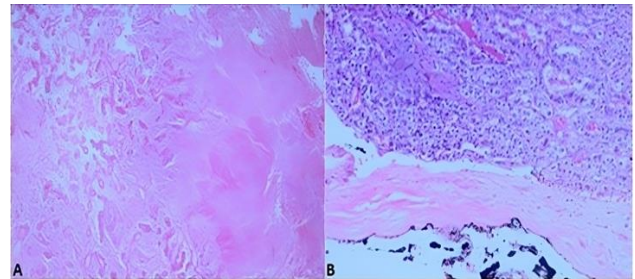


Figure 3. Microphotographs of resected parathyroid adenoma using hematoxylin-eosin stain at 10× (A) and 40× (B) magnification ([A] areas of necrosis and hemorrhage with hyalinized vascular structures are observed & [B] the follicular and trabecular arrangement of the adenoma cells, enclosed by a fibrous capsule with its outer edge marked with dark ink, is shown) (reprinted with permission of patient)

Following surgery, the patient developed hungry bone syndrome and was discharged with calcium and phosphorus supplements in the diet, as well as calcitriol 0.25 TID and calcium carbonate 500 TID. Subsequent follow-up showed normalization of serum calcium levels 2 years post-surgery, the patient initiated dialysis, which she currently undergoes.

DISCUSSION

The present case involves a female patient presenting with chest pain and compressive symptoms associated with a predominantly antero-superior mediastinal mass. In this clinical context, the differential diagnosis includes thymic origin tumors, lymphoproliferative processes such as lymphomas or granulomatous diseases, metastases or extension of a thyroid carcinoma that can occupy the superior mediastinum, among others. Ectopic parathyroid adenomas are rarely described, and even rarer are giant parathyroid adenomas; generally, patients with PHPT present with a small lesion without local mass effects unless an underlying carcinoma is present, which occurs in less than 1% of all PHPT cases [3, 5]. The female gender is predominantly affected, and there is evidence suggesting that estrogen may be involved in genomic actions favoring parathyroid cell proliferation [1].

During the diagnostic evaluation of the patient, we were struck by the elevated PTH levels (less than 4 times the upper limit of normal), which, along with the hypercalcemia were conclusive for the diagnosis of PHPT. We need to consider that these PTH concentrations can be found in patients with secondary hyperparathyroidism, such as those with stage IV CKD like our patient [6], which could be exacerbated by vitamin D deficiency, which is very common worldwide [7].

The cervicomedial tumor lesion found on the initial CT scan showed heterogeneous uptake on the 99mTc-sestaMIBI. The mediastinal localization of this tumor may correspond to its descent due to its own weight, given its relationship with the gland, unlike other cases where an ectopic tumor independent of healthy parathyroid glands is evident [8].

The patient's treatment had to be surgical due to the biochemical and anatomical complications presented. The tumor found was singular; however, cases of bilateral giant adenomas have been described [9]. After surgical resection, a tumor weighing 20 grams was obtained. According to the literature, tumors weighing over 3.5 grams can be classified as

giant adenomas, reaching exorbitant weights exceeding 200 grams [3, 10, 11]. The findings described in the pathology are consistent with parathyroid apoplexy. This rare event has been previously described in patients with parathyroid adenomas and even carcinomas, reporting the partial or complete remission of PHPT [12, 13].

The first documented description of parathyroid apoplexy was in 1946. Since then, only several dozen cases have been compiled in the literature [4]. The not so elevated levels of PTH, considering the tumor size, the presence of cystic and hemorrhagic degeneration; and the heterogeneous uptake of ^{99m}Tc-sestaMIBI; all of this reflected the presence of parathyroid apoplexy. The clinical presentation can vary, from pain without bleeding that resolves within days to evident bleeding that could be fatal [14]. It has been observed that there may be a period of hypocalcemia prior to the normalization of calcium levels in the blood [4]. Clinically, cough, dysphonia, and chest pain were present, resulting from airway compression, as reported in previous cases [15]. If there were acute anemia, hypotension, hypercalcemic crisis, or airway compromise, these would be indicators of emergency surgery [14].

In our case, the decreased renal function could account for the preoperative normophosphatemia as well as the difficulty in measuring 24-hour calciuria. PTH and calcium levels were elevated. It is known that there is a positive correlation between parathyroid tumor volume and preoperative intact PTH [16]. Given the tumor's extent, apoplexy was not sufficient for the biochemical resolution reported in other patients [4, 17]. However, cases reported with giant parathyroid adenomas usually have much higher PTH levels, reaching values exceeding 1,000 pg/ml [18]; parathyroid apoplexy may explain this difference. It is worth noting that although there is a tendency to find higher PTH levels in larger adenomas, studies comparing extreme sizes of parathyroid adenomas (< 300 mg vs. > 3,000 mg) demonstrate that the preoperative biochemical status is a poor predictor of size [19].

Our patient progressed from CKD stage IV to requiring dialysis 2 years after the surgery. In this regard, several studies have described that parathyroidectomy is associated with better long-term renal function outcomes [20], these primarily included patients with asymptomatic hyperparathyroidism who underwent surgery, whereas cases like ours were not included in those analyses.

Limitations

As limitations of the presented case, because of the kidney dysfunction, calcium in 24-hour urine collection, random urine calcium/creatinine ratio, and 25-hydroxy vitamin D could not be assessed. Additionally, until today, there are no clinical practice guidelines available to guide the approach and follow-up in these patients.

CONCLUSIONS

In conclusion, the diverse clinical presentation and challenging diagnostic features emphasize the necessity of considering giant parathyroid adenoma in the differential diagnosis of patients presenting with a mediastinal mass and hypercalcemia. This case report underscores the importance of recognizing parathyroid apoplexy as a rare complication of PHPT attributed to a giant parathyroid adenoma. Timely

imaging diagnosis and surgical intervention are imperative for optimal patient outcomes. Confirmation of the diagnosis relies on histopathology following surgery and appropriate monitoring of calcium-phosphorus metabolism and renal function in these patients.

Author contributions: **JP-I:** conceptualization, investigation, resources, supervision, & writing–review & editing; **MJC-Z:** methodology, investigation, writing–review & editing, & project administration; **FQ-R & JCA-G:** investigation & writing–review & editing; **JS-P:** investigation, supervision, & writing–review & editing; & **JEQ-A:** investigation & writing–original draft. All authors have agreed with the results and conclusions.

Funding: No funding source is reported for this study.

Ethical statement: The authors stated that the study was approved by the Ethics Committee of the Universidad Nacional de Trujillo School of Medicine on 13 March 2024 with approval code 127-2024-UNT-FM-C.E. The authors have the patient's authorization to publish her case as per CARE guidelines.

Declaration of interest: No conflict of interest is declared by the authors.

Data sharing statement: Data supporting the findings and conclusions are available upon request from the corresponding author.

REFERENCES

1. Yavropoulou MP, Anastasilakis AD, Panagiotakou A, Kassi E, Makras P. Gender predilection in sporadic parathyroid adenomas. *Int J Mol Sci.* 2020;21(8):2964. <https://doi.org/10.3390/ijms21082964> PMID:32331456 PMCID:PMC7216151
2. Marcocci C, Saponaro F. Epidemiology, pathogenesis of primary hyperparathyroidism: Current data. *Ann Endocrinol.* 2015;76(2):113-5. <https://doi.org/10.1016/j.ando.2015.03.015> PMID:25916761
3. Spanheimer PM, Stoltze AJ, Howe JR, Sugg SL, Lal G, Weigel RJ. Do giant parathyroid adenomas represent a distinct clinical entity? *Surgery.* 2013;154(4):714-9. <https://doi.org/10.1016/j.surg.2013.05.013> PMID:23978594 PMCID:PMC3787983
4. Efremidou EI, Papageorgiou MS, Pavlidou E, Manolas KJ, Liratzopoulos N. Parathyroid apoplexy, the explanation of spontaneous remission of primary hyperparathyroidism: A case report. *Cases J.* 2009;2:6399. <https://doi.org/10.1186/1757-1626-2-6399> PMID:20184676 PMCID:PMC2827073
5. Ghemigian A, Trandafir AI, Petrova E, et al. Primary hyperparathyroidism-related giant parathyroid adenoma (review). *Exp Ther Med.* 2022;23(1):88. <https://doi.org/10.3892/etm.2021.11011> PMID:34934453 PMCID:PMC8652388
6. Ketteler M, Block GA, Evenepoel P, et al. Diagnosis, evaluation, prevention, and treatment of chronic kidney disease–Mineral and bone disorder: Synopsis of the kidney disease: Improving global outcomes 2017 clinical practice guideline update. *Ann Intern Med.* 2018;168(6):422-30. <https://doi.org/10.7326/M17-2640> PMID:29459980
7. Galassi A, Ciceri P, Porata G, et al. Current treatment options for secondary hyperparathyroidism in patients with stage 3 to 4 chronic kidney disease and vitamin D deficiency. *Expert Opin Drug Saf.* 2021;20(11):1333-49. <https://doi.org/10.1080/14740338.2021.1931117> PMID:33993809
8. Zeng Z, Liao H, Luo F, Lin F. Mediastinal ectopic parathyroid adenoma. *QJM Mon J Assoc Physicians.* 2019;112(2):127-8. <https://doi.org/10.1093/qjmed/hcy262> PMID:30398661

9. Liu P, Vakharia N, Zacharia A, Rogers M, Tanweer F. Bilateral giant parathyroid adenoma in the absence of multiple endocrine neoplasia type 1. *Ann R Coll Surg Engl.* 2020; 102(6):e111-4. <https://doi.org/10.1308/rcsann.2020.0043> PMID:32233855 PMCID:PMC7388960
10. Al-Hassan MS, Mekhaimar M, El Ansari W, Darweesh A, Abdelaal A. Giant parathyroid adenoma: A case report and review of the literature. *J Med Case Reports.* 2019;13(1):332. <https://doi.org/10.1186/s13256-019-2257-7> PMID:31722742 PMCID:PMC6854700
11. Garuna Murthee K, Tay WL, Soo KL, Swee DS. A migratory mishap: Giant mediastinal parathyroid adenoma. *Am J Med.* 2018;131(5):512-6. <https://doi.org/10.1016/j.amjmed.2018.01.003> PMID:29360437
12. Natsui K, Tanaka K, Suda M, Yasoda A, Yonemitsu S, Nakao K. Spontaneous remission of primary hyperparathyroidism due to hemorrhagic infarction in the parathyroid adenoma. *Intern Med Tokyo Jpn.* 1996;35(8):646-9. <https://doi.org/10.2169/internalmedicine.35.646> PMID:8894740
13. Klimiuk PS, Mainwaring AR. Spontaneous biochemical remission in parathyroid carcinoma. *Br Med J.* 1980;281(6252):1394-5. <https://doi.org/10.1136/bmj.281.6252.1394-a> PMID:7437811 PMCID:PMC1715052
14. Van de Kerkhof J, Bijmens J, De Geeter F, Dick C, De Paepe P, Van den Bruel A. Parathyroid adenoma apoplexy mimicking a thyroid bleeding cyst: A seemingly innocent condition that can be life-threatening. *Endocrinol Diabetes Metab Case Rep.* 2023;2023(4):22-0385. <https://doi.org/10.1530/EDM-22-0385> PMID:38064892 PMCID:PMC10762588
15. Garrahy A, Hogan D, O'Neill JP, Agha A. Acute airway compromise due to parathyroid tumour apoplexy: An exceptionally rare and potentially life-threatening presentation. *BMC Endocr Disord.* 2017;17(1):35. <https://doi.org/10.1186/s12902-017-0186-2>
16. Nakai T, Horiuchi K, Okamoto T. Predicting tumor volume in primary hyperparathyroidism from preoperative clinical data. *J Clin Endocrinol Metab.* 2024;dgae185. <https://doi.org/10.1210/clinem/dgae185> PMID:38525667
17. Pereira FA, Brandão DF, Elias J, Paula FJ. Parathyroid adenoma apoplexy as a temporary solution of primary hyperparathyroidism: A case report. *J Med Case Reports.* 2007;1(1):139. <https://doi.org/10.1186/1752-1947-1-139> PMID:18021421 PMCID:PMC2204027
18. Mantzoros I, Kyriakidou D, Galanos-Demiris K, et al. A rare case of primary hyperparathyroidism caused by a giant solitary parathyroid adenoma. *Am J Case Rep.* 2018;19:1334-7. <https://doi.org/10.12659/AJCR.911452> PMID:30405093 PMCID:PMC6238585
19. Abdel-Aziz TE, Gleeson F, Sadler G, Mihai R. Dwarfs and giants of parathyroid adenomas—No difference in outcome after parathyroidectomy. *J Surg Res.* 2019;237:56-60. <https://doi.org/10.1016/j.jss.2018.12.021> PMID:30694792
20. Sant VR, ElNakieb Y, Lehmann CU, Rousseau JF, Maalouf NM. Patient characteristics, management, and outcomes in a novel cohort of primary hyperparathyroidism. *J Endocr Soc.* 2024;8(8):bvae096. <https://doi.org/10.1210/jendso/bvae096> PMID:38988672 PMCID:PMC11234201