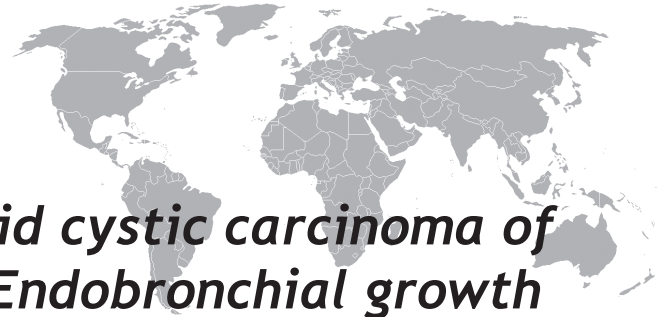

# A rare presentation of Adenoid cystic carcinoma of parotid gland as metastatic Endobronchial growth during Bronchoscopy with multiple 'Bilateral Cannon ball' lung metastasis in chest radiograph

Patil Shital<sup>1</sup>, Laxman Kasture<sup>2</sup>

## ABSTRACT

Adenoid cystic carcinoma are relatively less common type of salivary gland tumour including parotid gland, and is the only histological type having propensity to spread distantly by lympho-hematogenous and other 'classical perineural' spread. Adenoid cystic carcinoma as a primary salivary gland tumor arising in bronchus is known entity although is exceptionally rare. In this case report, 43 year male with past history of adenoid cystic carcinoma of left parotid gland which was operated 4 years back and received post-operative radiotherapy presented with shortness of breath clinically. We observed 'cannon ball opacities bilaterally' over chest radiograph and Endobronchial growth during bronchoscopy. Histopathology confirmed as a metastatic lung cancer. We recommend bronchoscopy of all the cases with bilateral cannon ball metastasis as it will help in diagnosis endobronchial growth.

Keywords: Bronchoscopy; Adenoid cystic carcinoma parotid; Cannon ball metastasis; Chest radiography, Metastasis

## INTRODUCTION

The major salivary glands include the parotid glands, the submandibular glands, and the sublingual glands. The majority of neoplasms arise in the parotid gland (70%), whereas tumors of the submandibular gland (22%) and sublingual and minor salivary glands (8%) are less common. The ratio of malignant to benign tumors varies by site as well: parotid gland, 80% benign and 20% malignant; submandibular gland and sublingual gland, 50% benign and 50% malignant; and minor salivary glands, 25% benign and 75% malignant (1).

Adenoid cystic carcinoma constitutes 10% of all salivary neoplasms, with two thirds occurring in the minor salivary glands. The histologic types of adenoid cystic carcinoma are tubular, cribriform, and solid, listed from best prognosis to worst. An indolent growth pattern and a relentless propensity for perineural invasion characterize adenoid cystic carcinoma. Regional lymphatic spread is uncommon, although distant metastases occur within the first 5 years after diagnosis and may remain asymptomatic for decades (1).

## CASE REPORT

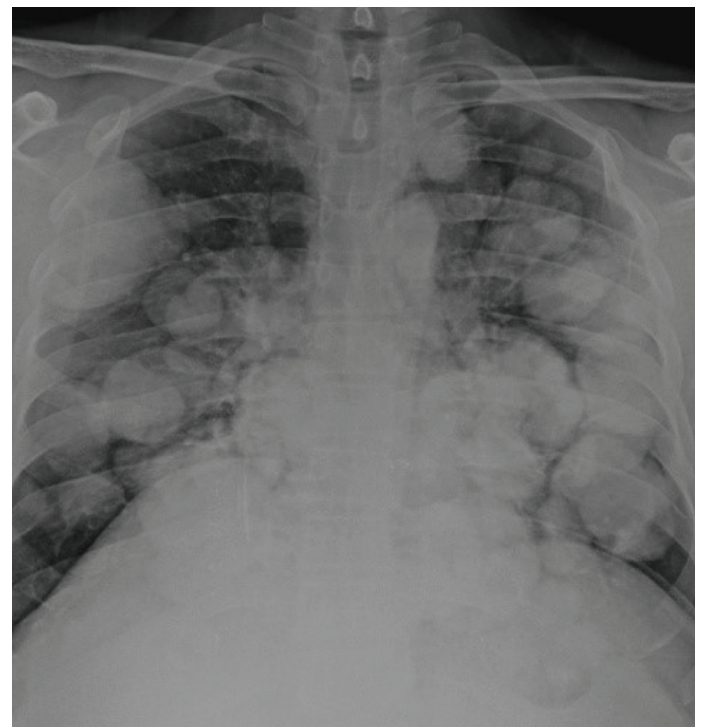49-year-old male, with past history of adenoid cystic carcinoma of left parotid gland undergone near total parotid gland removal and adjuvant radiotherapy attended outdoor clinic for gradual onset shortness of breath. After complete medical history, he was ex-smoker, nonalcoholic with intermittent tobacco chewer, developed shortness of breath which was progressive from grade I to grade IV over period of 2 years postoperative. General physical examination was normal, and cardiovascular system examination was also normal, while respiratory system examination we documented normal breath

sounds without any adventitious sounds.

Complete hemogram was showing Hemoglobin- 11gm%, total white blood cell counts were 6900/mm<sup>3</sup>

**Spirometry** was done which was showing mixed pattern (obstructive- restrictive airway disease)

**Chest X-ray** Postero-anterior view was as shown



Pulmonary Medicine Department<sup>1</sup>,  
Department of Radiodiagnosis<sup>2</sup>,  
MIMSR Medical college, Latur, Maharashtra, India

Received: 15.06.2015, Accepted: 06.07.2015

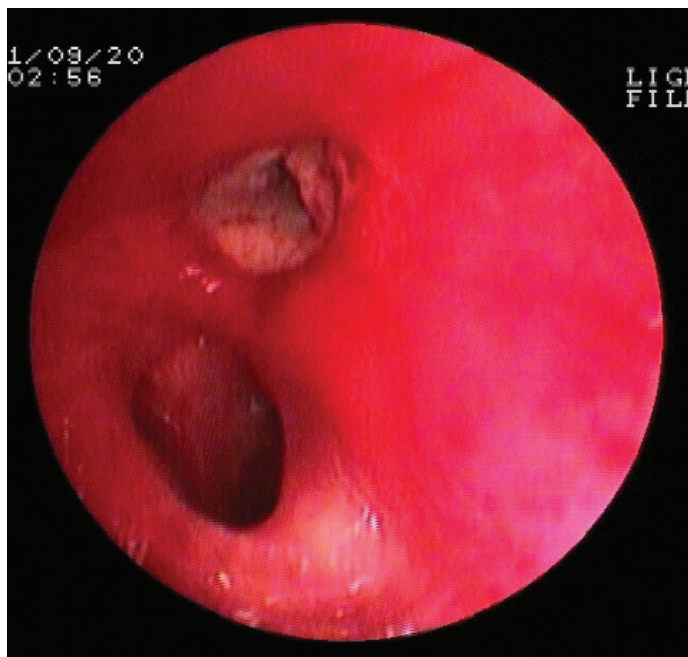
Correspondence: Patil Shital  
Pulmonary Medicine Department<sup>1</sup>  
MIMSR Medical college, Latur, Maharashtra, India

Email: drsvpatil1980@gmail.com

**Chest X-ray PA view-** showing bilateral, multiple ‘cannon ball’ opacities predominantly in mid & lower zone. These opacities are having clear margin demarcations with variable size and shapes.

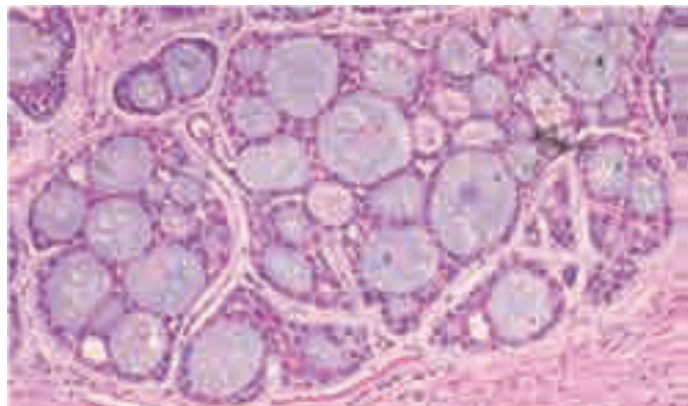
**PET CT scan-FDG uptake** was predominantly noted in both the lung fields with variable uptakes documented in liver, adrenals, pelvic bones, and brain.

**BRONCHOSCOPY**



Fiberoptic videobronchoscopy showing endobronchial growth in Lingular bronchus of left lung leading to near total occlusion of the lumen, bronchoscope could not be negotiated distal to growth.

**Histopathology report**



(Hematoxylin and eosin stain)

Histopathology examination showing cribriform growth pattern, with multiple bizarre pseudocysts surrounded by basaloid cells with hyperchromatic nuclei

Immunohistochemical stain for CD117 showed strongly positive result, around pseudocysts.

**DISCUSSION**

Adenoid cystic carcinoma (ACC) is a malignant neoplasm arising from the salivary glands. It accounts for 10-15% of all salivary gland neoplasms, representing 1–2% of malignant neoplasms of the head and neck (2). It is characterized by slow growth, diffuse invasion and potential to produce distant metastases, mainly to the lungs and bone. Approximately 31% of lesions affect minor salivary glands, the most common intraoral site being the hard palate, followed by the base of the tongue (3).

Over 95% of multiple pulmonary nodules on chest radiographs are metastases or post infectious

granulomas. The larger and more variable the size of the nodules, the more likely they are to be neoplastic. This remark does not apply to nodules too small to be seen on chest radiographs and

found only on CT. Metastases are usually spherical and have well-defined outlines, although metastases with irregular margins and poorly defined edges are occasionally encountered. Metastases vary considerably in size (4, 5).

The following points may help limit the diagnostic possibilities: (4, 5)

1. In patients with metastases the presence of an extra-thoracic primary tumor is usually known or at least suspected because of clinical findings.
2. A cluster of two or more small (<1 cm) pulmonary nodules within 1 cm of each other in a focal area of the lung are highly likely to be infectious or inflammatory in origin.

**Differential diagnosis of multiple pulmonary nodules/ masses (6)**

1. **Neoplastic**
  - Malignant-Metastatic carcinoma or sarcoma, Lymphoma, Multifocal neoplasms, e.g. Kaposi sarcoma and bronchioloalveolar cell carcinoma
  - Benign-Hamartomas, chondromas, Laryngeal papillomatosis, Benign metastasizing leiomyoma
2. **Inflammatory**
  - Infective-Granulomas, e.g. tuberculosis, histoplasmosis, cryptococcosis, coccidioidomycosis, nocardiosis, Round pneumonias, particularly fungal and opportunistic infections, Lung abscesses, especially septicemic, Septic infarcts, Atypical measles, Hydatid cysts, Paragonimiasis
3. **Noninfective** - Rheumatoid arthritis, Caplan syndrome, Wegener granulomatosis, Sarcoidosis, Drug-induced
4. **Congenital** - Arteriovenous malformation
5. **Miscellaneous** - Progressive massive fibrosis, Hematomas, Amyloidosis, Pulmonary infarcts, Mucoïd impactions

We have referred case to the oncology unit, undergone palliative radiotherapy. After 14 cycles of radiotherapy, cannon ball metastasis were shown response and shown acceptable radiological response. Clinically respiratory parameters are fairly stable with acceptable shortness of breath.

In Conclusion: Although adenoid cystic carcinoma of parotid has propensity to spread distantly, either hematogenous or perineural; lung metastasis is rare. We have documented extremely rare occurrence of ‘bilateral cannon ball’ metastasis caused because of adenoid cystic carcinoma of lung. Additionally, we also documented ‘endobronchial metastases’ of a case with bilateral cannon ball opacity which is again a rare observation in adenoid cystic carcinoma of parotid gland.

We recommend bronchoscopy of all the cases with bilateral cannon ball metastasis as it will diagnose endobronchial growth which will be the commonest cause of respiratory symptoms in these cases.

## REFERENCES

1. Sabiston Textbook of Surgery, 18th ed., The Biological Basis of Modern Surgical Practice. Townsend CM, Beauchamp RD, Evers BM, eds. Philadelphia: WB Saunders, 2007
2. Kim KH, Sung MW, Chung PS, Rhee CS, Park CL, Kim WH. Adenoid cystic carcinoma of the head and neck. Arch Otolaryngol Head Neck Surg 1994; 120:721-6.
3. Khafif A, Anavi Y, Aviv J, Marshak G. Adenoid cystic carcinoma of the salivary glands: a 20-year review with longterm follow-up. Ear Nose Throat J 2005;84: 662–7
4. Ishihara T, Kikuchi K, Ikeda T, et al. Metastatic pulmonary diseases: biologic factors and modes of treatment. Chest 1973; 63:227-232.
5. MacMahon H, Austin JH, Gamsu G, et al. Guidelines for management of small pulmonary nodules detected on CT scans: a statement from the Fleischner Society. Radiology 2005; 237:395-400.
6. Hansell DM, Bankier AA, MacMahon H, McLoud TC, Müller NL and Remy J. Fleischner Society: Glossary of Terms for Thoracic Imaging. Radiology 2008; 246: 697-722.